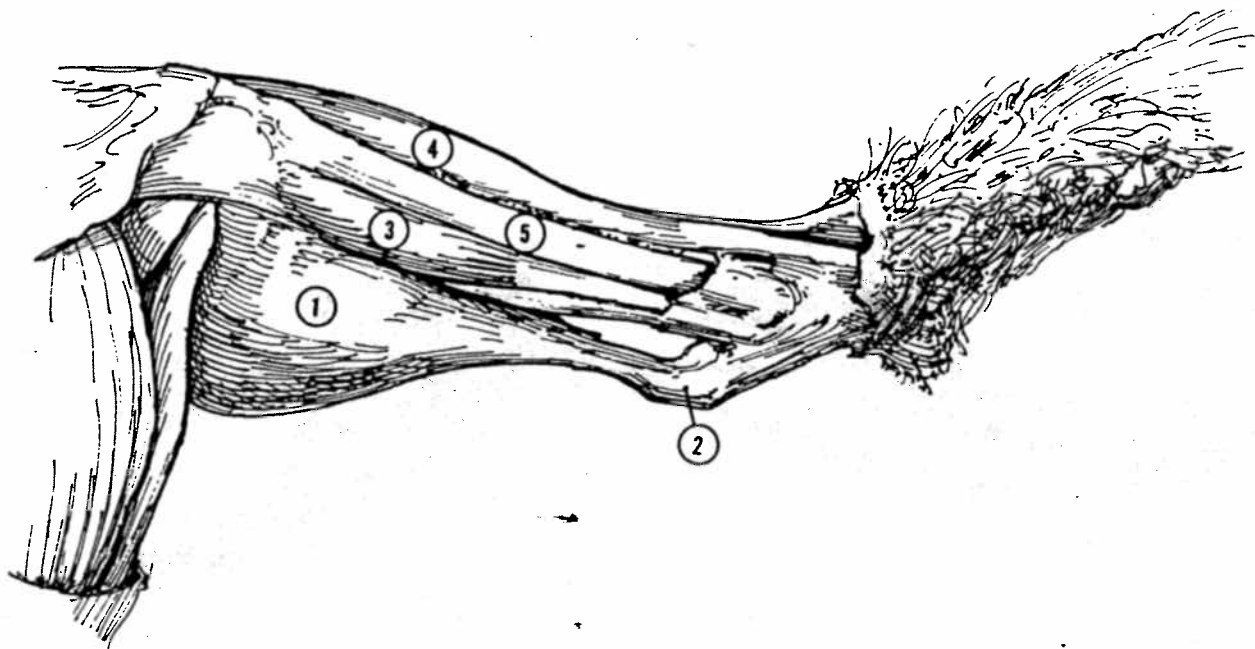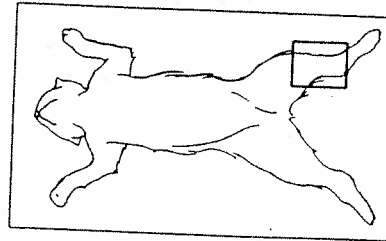


Figure 18-1b Superficial lower leg muscles, medial surface.

1. Gastrocnemius (gas'-trok-NE-mê-us)
2. Achilles tendon (a-KIL-êz)
3. Flexor digitorum longus (dij-i-TÔ-rum)
4. Tibialis anterior (tib'-ê-AL-is)
5. Tibia (bone)



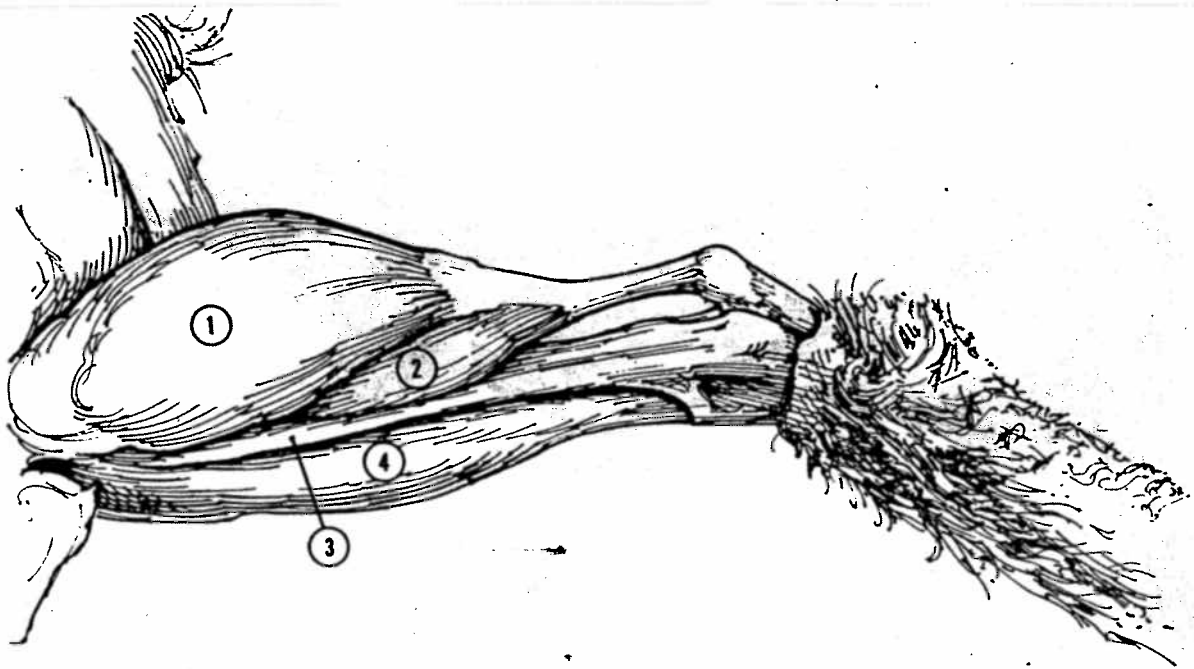


Figure 18-2b Superficial lower leg muscles, lateral surface.

1. Gastrocnemius
2. Soleus (SŌ-lē-us)
3. Peroneus (per'-ō-NĒ-us)
4. Extensor digitorum longus

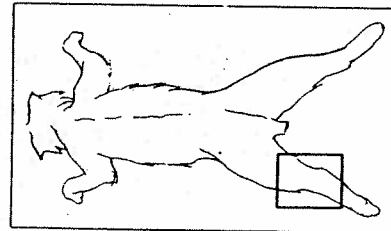


Table 18-1 Superficial Lower Leg Muscles of the Cat

Muscle	Origin	Insertion	Action
Gastrocnemius	Knee fascia and distal end of femur	Calcaneus by Achilles tendon	Extends foot
Flexor digitorum longus	Distal end of tibia and head and shaft of fibula	Tendons on all digits	Flexes digits
Tibialis anterior	Proximal ends of tibia and fibula	First metatarsal	Flexes foot
Soleus	Proximal end of fibula	Bases of metatarsals	Extends foot
Peroneus	Proximal end of fibula	Bases of metatarsals	Flexes foot
Extensor digitorum longus	Distal end of femur	All phalanges	Extends toes